

PennHIP Report

Referring Veterinarian: Dr Andrew Gendler	Clinic Name: WestVet Animal Emergency and Specialty Center
Email: agendler@westvet.net	Clinic Address: 5019 N Sawyer Avenue Garden City, ID 83714
	Phone: (208) 375-1600
	Fax: (208) 375-1606

Patient Information

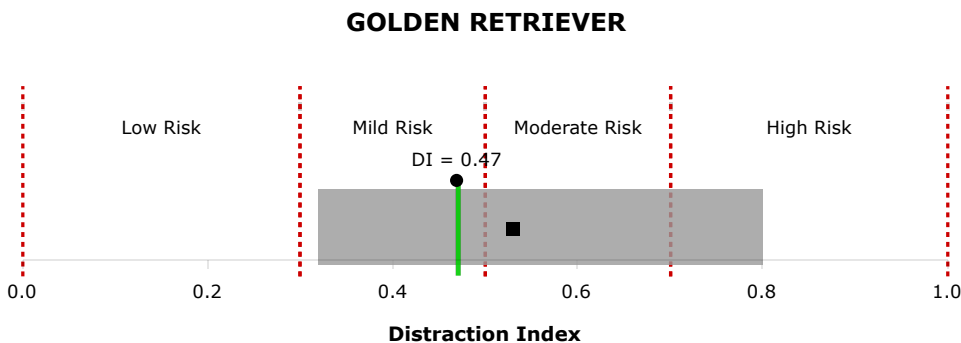
Client: JARVIS, SAMANTHA	Tattoo Num:
Patient Name: MAGGIE	Patient ID: 114733-MAGGIE
Reg. Name: MAGNOLIA OF BOXWOOD HOUSE	Registration Num: SS09584901
PennHIP Num: 147722	Microchip Num: 985113001590742
Species: Canine	Breed: GOLDEN RETRIEVER
Date of Birth: 03 Oct 2018	Age: 24 months
Sex: Female	Weight: 57.3 lbs/26 kgs
Date of Study: 06 Oct 2020	Date Submitted: 07 Oct 2020
Date of Report: 08 Oct 2020	

Findings

Distraction Index (DI): Right DI = 0.42, Left DI = 0.47.
 Osteoarthritis (OA): **No radiographic evidence of OA for either hip.**
 Cavitation/Other Findings: No cavitation present.

Interpretation

Distraction Index (DI): The laxity ranking is based on the hip with the greater laxity (larger DI). In this case the DI used is 0.47.
 OA Risk Category: The DI is between 0.31 and 0.49. This patient is at mild risk for hip OA.
 Distraction Index Chart:



BREED STATISTICS: This interpretation is based on a cross-section of 21663 canine patients of the GOLDEN RETRIEVER breed in the AIS PennHIP database. The gray strip represents the central 90% range of DIs (0.32 - 0.80) for the breed. The breed average DI is 0.53 (solid square). The patient DI is the solid circle (0.47).

SUMMARY: The degree of laxity (DI = 0.47) falls within the central 90% range of DIs for the breed. This amount of hip laxity places the hip at a mild risk to develop hip OA. **No radiographic evidence of OA for either hip.**